

Titanium-reinforced Polytetrafluoroethylene Membrane Combined With Inorganic Polyphosphate Induces Exophytic Bone Formation In Rabbit Calvaria

J.S. Kim^{1a}, S.Y. Na¹, Y.H. Kwon¹, J.B. Park¹, J.H. Chung¹, M.I. Cho², Y. Herr^{1b}

¹Department of Periodontology, School of Dentistry, Kyung Hee University, #1 Hoeki-dong, Dongdaemoon-gu, Seoul, 130-702, Korea

²Department of Oral Biology, School of Dental Medicine, State University of New York at Buffalo, B10 Foster Hall, Buffalo, NY 14214, U.S.A.

*kjsperio@hanmail.net, yherr@khu.ac.kr(correspondence)

Abstract

The purpose of this study was to examine if the application of titanium-reinforced expanded polytetrafluoroethylene (TR-ePTFE) membrane combined with bovine bone mineral (BBM) soaked in inorganic polyphosphate promotes exophytic bone formation in rabbit calvaria. For this purpose, a total of 8 rabbits were used, and rectangular decorticated calvaria sites were created using a round carbide bur. In the control group, rectangular parallelepiped-shaped TR-ePTFE membranes (RPTPMs) were filled with BBM soaked in saline and placed on the decorticated sites and fixed with metal pins. In the experimental groups, RPTPMs were filled with BBM soaked in 4%, 8% and 16% inorganic polyphosphate prior to fixing with metal pins. Animals were sacrificed at 4 and 8 weeks after surgery, and new bone formation was assessed by histomorphometric as well as statistical analysis. The results indicated that at 8 weeks, all the experimental groups demonstrated exophytic bone formation. At 8 weeks, the 8% polyphosphate group revealed the most new bone formation ($p < 0.05$). On the basis of these findings, we conclude that inorganic polyphosphate has a promoting effect on bone regeneration, possibly by enhancing osteoinductivity of the decorticated wound area and osteoconductivity of the carrier material, but not much as we expected.

Introduction

A sufficient quantity of bone available for implant placement is an essential prerequisite for the success of dental implants as well as aesthetic results. The results of the studies regarding vertical augmentation of the alveolar ridge are controversial, but vertical augmentation has been achieved by placing an ePTFE membrane on alveolar ridge. These studies indicated that ePTFE membranes provide properties such as biocompatibility, sufficient stiffness, stability and peripheral sealing which are needed for new bone formation. Inorganic polyphosphate induces the expression of both osteopontin and osteocalcin and has a positive effect on the induction of ALPase activity, therefore promotes calcification in MC3T3-E1 cells. Bone graft materials have been used in combination with augmentation membranes for guided bone regeneration. In this study, we examined the efficacy of application of TR-ePTFE membrane in combination with BBM soaked in inorganic polyphosphate on exophytic bone formation in rabbit calvaria using histomorphometric analysis.

Methods

The materials used in this study include RPTPM (TR-9W, W.L. Gore & Associates Inc., Flagstaff, AR, USA, inner height: 5 mm; length: 8 mm; width: 5 mm), BBM (Bio-Oss®, Geistlich, Wolhusen, Switzerland), and Poly P75 (sodium polyphosphate, Sigma, St. Louis, MO, USA). Also, a total of 8 male white rabbits were used. Under general anesthesia through an IM injection of xylazine/ketamine, the skin of the calvarium was infiltrated with 2% lidocaine HCl. After the skin-periosteal flap was reflected, decorticated sites (about 1 mm in depth, 8 mm x 5 mm in size) were created using a round carbide bur at the both sides from the sagittal suture. In the control group, RPTPMs were placed on the decorticated sites with BBM soaked in saline and fixed with metal pins (Fig. 1). In the experimental groups, RPTPMs were filled with BBM soaked in 4%, 8%, 16% inorganic polyphosphate respectively and were then placed on the wound sites. At 4 and 8 weeks after surgery, animals were sacrificed, and the surgical sites with RPTPMs were dissected out, fixed in 4% buffered formalin, dyed using a Villanueva staining technique, and processed for embedding in plastic resin. Three serial 500 μ m-thick transversal sections were cut from the central part of RPTPM using a milling saw, and ground to a thickness of about 80 μ m. For histomorphometric analysis, a PC based image analysis system (TDI Scope Eye program, Techsan Int Co., Seoul, Korea) was used to assess newly formed bone and residual graft materials (Fig. 2). The statistical significance between two experimental time periods were analyzed by Mann Whitney U test, while that among different groups within the same experimental time periods was analyzed by Kruskal-Wallis test.

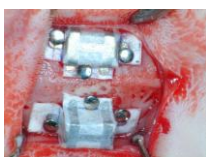

Fig. 1. TR-ePTFE membranes on calvarium

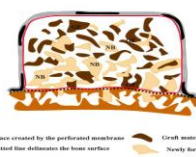

Fig. 2. A schematic diagram showing the components subjected to histomorphologic analysis

RESULTS

Histological Analysis. Overall, the wound spaces covered by TR-ePTFE membranes were well maintained without collapse and peripheral sealing was well maintained by the metal pins (Figs. 3-10). Control sites showed a small amount of new bone formation from the residual bone surface and BBM was not absorbed and surrounded by fibrous connective tissue (Figs. 3 and 4). In the 4%, 16% polyP groups, the remaining BBM particles were surrounded by fibrous connective tissue without resorption at 4, 8 weeks. A small amount of new trabecular bone was formed near the residual bone surface (Figs. 5 and 6, 9 and 10).

In the 8% polyP groups, BBM particles were surrounded by fibrous connective tissue, but significantly intermingled with newly formed trabecular bone at 8 weeks (Figs. 7 and 8).

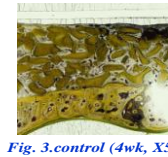


Fig. 3. control (4wk, X5)

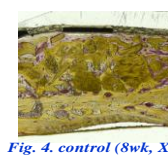


Fig. 4. control (8wk, X5)



Fig. 5. BBM+4%polyP (4wk, X5)

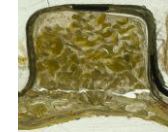


Fig. 6. BBM+4%polyP (8wk, X5)



Fig. 7. BBM+8%polyP (4wk, X5)



Fig. 8. BBM+8%polyP (8wk, X5)



Fig. 9. BBM+16%polyP (4wk, X5)



Fig. 10. BBM+16%polyP (8wk, X5)

Histomorphometric and Statistical Analysis (Table 1). At 4 weeks, new bone formation increased by 3.36 ± 0.72 % in the control group, 3.84 ± 0.94 % in the 4% polyphosphate group, 3.73 ± 0.39 % in the 8% polyphosphate group, and 4.29 ± 7.06 % in the 16% polyphosphate group. No statistical difference was observed between control and experimental groups. At 8 weeks, new bone formation increased by 7.33 ± 0.20 % in the control group, 10.49 ± 0.77 % in the 4% polyphosphate group, 14.38 ± 2.48 % in the 8% polyphosphate group, and 7.06 ± 0.79 % in the 16% polyphosphate group. Statistically significant differences were observed between control and experimental groups ($P < 0.05$). At 4 weeks, the residual graft materials accounted for 36.13 ± 0.66 % in the control group, 36.98 ± 0.65 % in the 4% polyphosphate group, 38.16 ± 4.60 % in the 8% polyphosphate group, and 33.75 ± 5.53 % in the 16% polyphosphate group. At 8 weeks, the residual graft materials further decreased to 35.24 ± 1.51 % in the control group, 34.68 ± 5.54 % in the 4% polyphosphate group, 32.76 ± 1.41 % in the 8% polyphosphate group, and 32.76 ± 1.41 % in the 16% polyphosphate group. The differences among groups were not statistically significant ($P < 0.05$).

Table 1. Histomorphometric analysis

	New bone formation(%)		Residual graft material(%)	
	4w(n=4)	8 w*(n=4)	4w(n=4)	8w(n=4)
BBM (control)	3.36 ± 0.72	7.33 ± 0.20	36.13 ± 0.66	35.24 ± 1.51
BBM +4%polyP	3.84 ± 0.94	10.49 $\pm 0.77^*$	36.98 ± 0.65	34.68 ± 5.54
BBM +8%polyP	3.73 ± 0.39	14.38 $\pm 2.48^*$	38.16 ± 4.60	35.65 ± 0.53
BBM +16%polyP	4.29 ± 1.53	7.06 $\pm 0.79^*$	33.75 ± 5.53	32.76 ± 1.41

* Statistically significant difference ($p < 0.05$) was found not only between two experimental time periods, but also among experimental groups.

Discussion and conclusion

We used TR-ePTFE membranes as augmentation membranes for guided bone regeneration. They effectively maintained and protected the regeneration space during the healing without any sign of inflammation. Although all the experimental groups demonstrated an increase in new bone formation at 4 and 8 weeks compared to the control group, only the new bone formation at 8 weeks revealed a statistical difference between the two groups. The 8% phosphate group exhibited the most new bone formation compared to other groups ($p < 0.05$). The majority of BBM remained unresorbed even at 8 weeks and thus showed little new bone formation. We conclude that inorganic polyphosphate has a promoting effect on bone regeneration, possibly by enhancing osteoinductivity of the decorticated wound area and osteoconductivity of the carrier material, but not much as we expected. Further study is required to examine the most effective carrier material in the same experimental model.

Acknowledgements

This study was supported by a grant of the Korea Health 21 R&D Project, Ministry of Health & Welfare, Republic of Korea (03-PJ1-PG1-CH08-0001).